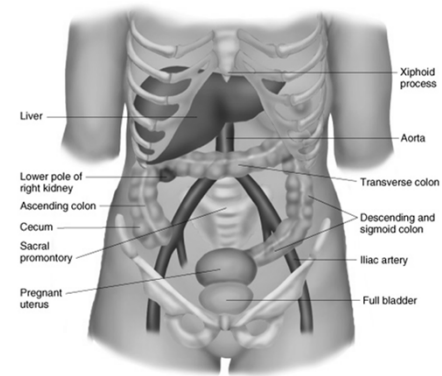


## LEARNING OBJECTIVES

- To recognize important and clinically validated findings
- To understand their mechanism of formation
- To develop a differential diagnosis
- To link some of these findings to historical figures/celebrities



- Lymphnodes
- Abdominal Aorta
- Gallbladder
- Pancreas
- Ascites
- Peritoneum and Acute Abdomen
- Chronic Liver Disease

## Examining the Supraclavicular Fossa

### How to Palpate for Supraclavicular Nodes

- The best way is to have the patient sitting up, with his head straight forward and his arms kept down (this is done to minimize the risk of misidentifying a cervical vertebra or a neck muscle for a node).
- Palpation from behind usually allows the examiner's hand to best adapt to the patient's anatomy, and is probably preferable.
- Palpation from the front, on the other hand, should be attempted in the *supine* patient (in this position, the change in gravity may mobilize the node, thus making it more accessible).
- Finally, asking the patient to perform a Valsalva maneuver, or simply to cough, may "pop out" a deeply seated node, bringing it within reach of the examiner's fingers.

### Supraclavicular Nodes

- A localized node in the supraclavicular fossa (either right or left) is a very important finding. It is usually an indicator of metastatic involvement from ipsilateral breast or lung cancers (a *right* supraclavicular node, however, may also indicate cancer of the *left* lower lobe of the lung, due to bilateral crossed drainage).
- If located in the *left* supraclavicular fossa, a palpable lymph node may also represent spread from a large number of intraabdominal or intrapelvic tumors. From this standpoint, a large left supraclavicular node is often referred to as a sentinel node (signaling a deep-sited carcinoma), or as a *Troisier's node*.

### Troisier versus Virchow's Nodes

- *Troisier's node* (or sign) is a palpable single *left* supraclavicular node, frequently located behind the clavicular head of the sternocleidomastoid muscle. This usually represents metastatic involvement from either an ipsilateral breast or lung carcinoma, or from an esophageal tumor. Most commonly, however, reflects spread from intra-abdominal or intra-pelvic malignancies, such as stomach, intestine, liver, kidneys, pancreas and even testicles and endometrium.
- When representing a metastasis from a *gastric* carcinoma, this node is often referred to as *Virchow's Node*.

### THE UMBILICUS

- Purplish Discoloration of the Umbilicus:
  - Cullen's sign (periumbilical ecchymosis)
  - Grey-Turner's sign (bilateral flank ecchymosis)

### THE UMBILICUS

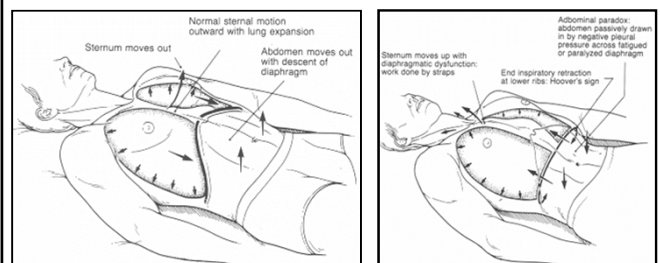
- Purplish Discoloration of the Umbilicus:
  - Cullen's sign (periumbilical ecchymosis)
  - Grey-Turner's sign (bilateral flank ecchymosis)
- Sister Joseph Nodule (Stomach, Ovary, Colon, Rectum, Pancreas)

### SISTER JOSEPH NODULE

- It is a periumbilical nodule, or hard mass, detectable by either inspection and/or palpation of the navel. It is clinically very valuable.
- It represents metastatic involvement of the paraumbilical nodes from intra-pelvic or intra-abdominal malignancies, most commonly stomach or ovary .
- This finding was first reported in article published in 1928 by W.J. Mayo. The article was based on an observation of Mayo's first surgical assistant, Sister Joseph (born Julia Dempsey in Salamanca NY) of St. Mary's Hospital.

### THE ABDOMINAL WALL (cont.)

- Abdominal Paradox and Respiratory Alternans

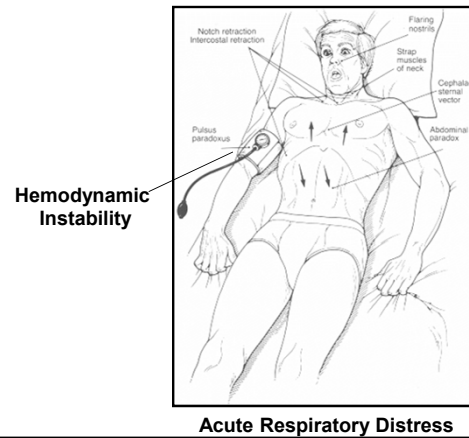


Normal Respiration

Abdominal Paradox

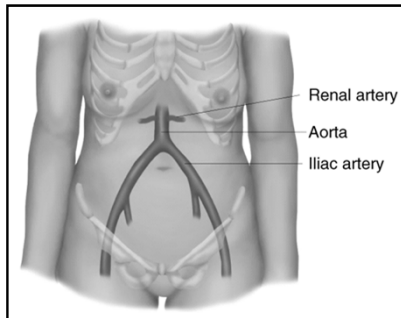
## ABNORMALITIES IN THE USE OF RESPIRATORY MUSCLES (1)

- *Abdominal Paradox* - a.k.a
  - Paradoxical Respiratory Breathing
  - Respiratory paradox
- *Respiratory Alternans*

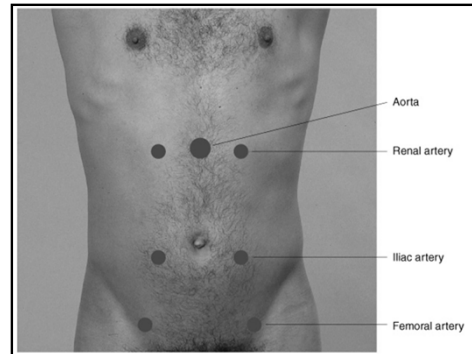


**Acute Respiratory Distress**

## LISTENING POINTS – BRUITS



## LISTENING POINTS FOR BRUITS IN THE ABDOMEN

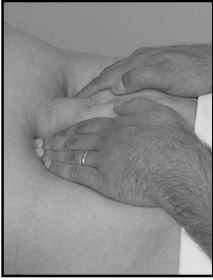

## CASE

- An overweight and pipe-smoking German physicist presents to your office c/o abdominal pain.
- Exam is positive for a laterally expansive and pulsatile upper abdominal (epigastric) mass, 6 cm in diameter.
- You recommend surgery, but also warn about its risks.
- The patient listens to you, then says, "Doctor, let it burst..."

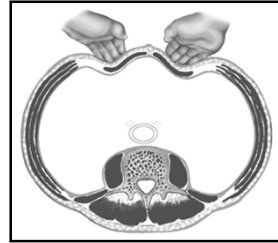- What is the diagnosis?
- Who was the patient?
- What happened to him?
- What happened to his brain?

## ABDOMINAL AORTIC ANEURYSM

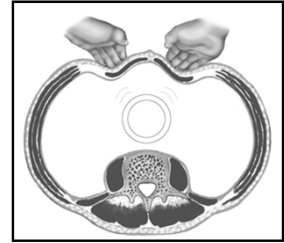


- Aneurysms of the infrarenal abdominal aorta are among the top ten causes of death.
- They have genetic and familial predisposition.
- By age 80, over 5% of white U.S. males will have one.
- White men over age 55 are at the greatest risk
- African-Americans and women are at the lowest risk
- If rupture occurs, < 20% of patients will survive
- 5-6 cm aneurysms are likely to rupture and should be repaired.

## IDENTIFYING AORTIC PULSATIONS



Normal



Upper Abdominal Mass

- 3-5 cm, *specific* but not sensitive (1/5)
- > 5 cm, very sensitive (4/5)
- Umbilical girth > 100 cm renders the exam almost impossible

- Rushed to Princeton Hospital because of severe abdominal pain on April 13, 1955.
- Diagnosed with a ruptured AAA.
- On April 18 (1 AM) develops labored respiration and dies.
- Following his wishes, remains are cremated the very same day, and ashes put down at an unknown place.
- Brain, however, disappears.

- Einstein had actually been diagnosed as having AAA in December 1948, after presenting to the *Brooklyn Jewish Hospital* with abdominal pain and vomiting.
- At that time, Dr. Rudolph Nissen (famous for developing a widely used operation to prevent esophageal reflux) had done an exploratory laparotomy and found a "grapefruit-sized" aneurysm, which he had then wrapped in polyethylene cellophane.
- With that Einstein managed to live six more years, during which he was offered (and declined) the presidency of Israel. Yet, he kept having bouts of "cholecystitis".
- At re-hospitalization in 1955, he was, once again, offered heroic surgery. Yet, he turned it down by saying: "I want to go when I want. It is tasteless to prolong life artificially. I have done my share and it is time to go. I will do it *elegantly*."
- Autopsy revealed a normal gallbladder and a huge abdominal aneurysm.
- Gallbladder compression by the aneurysm had simulated the cholecystitis attacks\*.

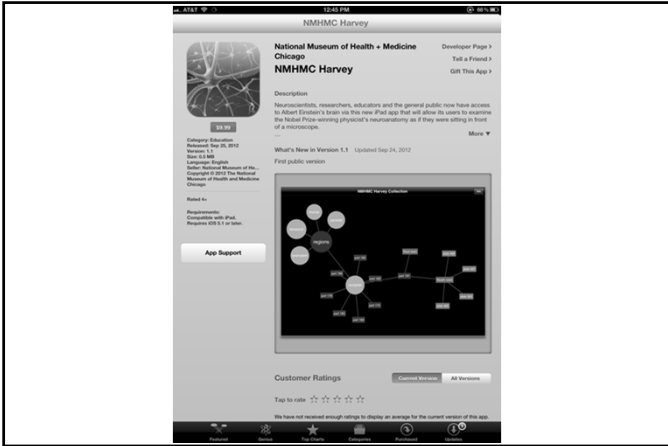
\* JJ Chandler: The Einstein sign: the clinical picture of acute cholecystitis caused by ruptured abdominal aortic aneurysm. NEJM 1984; 310 (23):1538

"Music helps him when he is thinking about his theories.

He goes to his study, comes back, strikes a few chords on the piano, jots something down, returns to his study."

(Elsa Einstein)

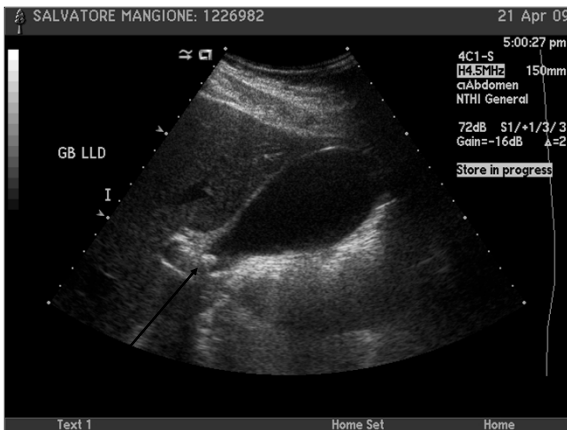
- Einstein's brain disappeared after autopsy in rather mysterious circumstances.
- It was only much later that it was discovered that it had been hidden away by Dr. Thomas Harvey, the Princeton pathologist who had performed the autopsy.
- Forty years after Einstein's death, 86-year old Dr. Harvey, drove Einstein's brain cross country on a rented Buick to present it to Einstein's granddaughter.
- Along with Dr. Harvey also drove an Italian-American journalist/chauffer, Michael Paterniti, who later described the brain's discovery and final trip in *Driving Mr. Albert: A Trip Across America With Albert Einstein's Brain*.



## EVALUATION OF THE GALLBLADDER

## EVALUATION OF THE GALLBLADDER


- In contrast to the liver, examination of the gallbladder by physical diagnosis still occupies an important role.
- The gallbladder is usually not palpable, but becomes detectable in case of pathology.
- Two maneuvers/findings have been traditionally linked to the assessment of a diseased gallbladder:
  1. Murphy's sign
  2. Courvoisier's Law



**VANITAS VANITATUM - OMNIA VANITAS\***  
(Vanity of vanities; all is vanity)



\* Ecclesiastes 1:2 – Transience of Life; futility of pleasure; certainty of death.



\* Ecclesiastes 1:2 – Transience of life, futility of pleasure, certainty of death.

## MURPHY'S SIGN

- Painful arrest in inspiration, triggered by palpation of the edge of an inflamed gallbladder.
- To elicit this sign, the patient lies supine and takes a deep breath, while the examiner presses his/her fingers under the right lower costal margin and along the mid-clavicular line (point of location of the gallbladder), aiming towards the patient's head.
- The encounter between the examiner's fingertips and the inflamed edge of the gallbladder causes pain and a reflex arrest in inspiration.

## MURPHY'S SIGN (cont.)

- Murphy's sign has sensitivity and specificity for cholecystitis of 50 to 80%, with specificity being a little higher than sensitivity.
- Its significance increases in patients whose presentation is consistent with cholecystitis (= nausea, vomiting and right upper quadrant pain), and decreases in those with back tenderness, where other conditions (like pancreatitis or renal disease) are more likely.
- Hence, the sign is still relatively helpful if *present*, but not as much as in the original description by Dr. Murphy.
- Moreover, ultrasound now provides an enticing alternative, not only for the identification of cholelithiasis, but also for eliciting a *sonographic* Murphy's sign (sensitivity 87%).

## OTHER SIGNS OF CHOLECYSTITIS

- In addition to the previous signs, patients with cholecystitis may also exhibit other findings.
- For example they may have an *area of hypersensitivity* over the right costophrenic angle (Boas' sign) – sensitivity only 7%.
- At times they may also exhibit an *audible rub* over the edge of the gallbladder.
- They rarely have a *palpable and tender right upper quadrant mass*, (see Courvoisier's law).

- F-at
- F-ertile
- F-emale
- F-orty (or F-ifty)

## Gallbladder Disease



Friday, Oct. 12, 1965

### Surgery: The Presidential Cholecystectomy

Lurking half-hidden behind the lower edge of the liver, the pear-shaped gall bladder serves as a storehouse for an essential substance—the thick, greenish bile (or gall) that the liver manufactures to aid in the long and complex process of digestion. In the young, the gall bladder usually stays healthy and does its job quietly and uncomplainingly. By the time a man reaches his middle forties, his gall bladder becomes increasingly subject to infection (cholecystitis) or filling up with gallstones (cholelithiasis), or both.

The "stones" range in size from a grain of sand to a marble. They are made up of cholesterol, bile acids and other digestive substances, and when they interfere with the flow of fat-digesting bile to the duodenum (see diagram), they may cause sharp and colicky pain, especially after a heavy, fatty meal. This is what happened to President Lyndon Johnson at his Texas ranch early last month.

Live Without It: X rays ordered by the White House physician, Vice Admiral George G. Burbley, confirmed his suspicion of a poorly functioning gall bladder. A second set of X rays, forwarded to the President's longtime friend and personal physician, the Mayo Clinic's Dr. James C. Cain, gave added evidence that the gall bladder contained stones. Since some bile always passes directly through the common duct from the liver to the duodenum, and the duct seems able to develop some storage capacity of its own, man can live without his gall bladder. Thus surgery to remove the offending organ (cholecystectomy), far from being a desperate last resort was the doctors' first choice.

October 1965

### CASE

- You are evaluating a 72 year old Italian actor.
- He is the self-deprecating son of a Roman carpenter, who escaped from a Nazi labor camp before rising to the role of *Latin Lover*.
- Yet, he claims that he has always been the one being dumped rather than the dumper.
- Faye Dunaway did indeed dump him by saying: "Either you shit or you get off the pot", but Catherine Deneuve remained instead faithful, and even sat at his bedside at the time of death.
- Still, a staunch Catholic, he remained loyally married to his Italian wife of 45 years.

### CASE

- You are evaluating a 72 year old Italian actor.
- He is the self-deprecating son of a Roman carpenter, who escaped from a Nazi labor camp before rising to the role of *Latin Lover*.
- Yet, he claims that he has always been the one being dumped rather than the dumper.
- Faye Dunaway did indeed dump him by saying: "Either you shit or you get off the pot", but Catherine Deneuve remained instead faithful, and even sat at his bedside at the time of death.
- Still, a staunch Catholic, he remained loyally married to his Italian wife of 45 years.
- On exam he is jaundiced, and with a painless but palpable gallbladder.

Marcello Mastroianni


### COURVOISIER'S LAW

- In *painless* jaundice, an *enlarged, palpable* and *non-tender* gallbladder is *not* due to *cholelithiasis*, but to *cancer* of either the biliary tract or the pancreatic head.
- There are two possible explanations for why the gallbladder of patients with cholelithiasis remains small.
  1. Recurrent biliary colics caused by stone migration lead to stiffening of the gallbladder wall.
  2. Biliary colics caused by stones tend to be symptomatic and acted upon. They rarely produce complete ductal obstruction.
- The first mechanism was proposed by Courvoisier himself and is probably not as accurate as the second mechanism.

### COURVOISIER'S LAW – CLINICAL SIGNIFICANCE

- More recent series suggest lower *sensitivity* for malignant obstructions than Courvoisier's original data (25-50%), but still excellent specificity (80-90%).
- For example, only 50% of patients with jaundice caused by pancreatic carcinoma have a clinically palpable gallbladder (a value that increases to 80% if operative or autopsy enlargement is taken into consideration). At surgery, 42% of jaundiced patients with common duct stones have an enlarged gallbladder, as opposed to 80% of those with a pancreatic tumor.
- Still, a palpable and non-tender gallbladder in a jaundiced patients should be interpreted as a strong indication that jaundice is *not* due to hepatocellular disease, but instead to an *extrahepatic* obstruction of the biliary tract. Although not very sensitive, this finding is highly specific. Whether the obstruction is caused by tumor or stone, however, is difficult to say, even though the likelihood of tumor is a bit higher.

### CASE

- You are evaluating a 57-year old German musician who presented to your office complaining of a distended belly and dropsy.
- Interview is difficult because the patient is profoundly hard of hearing and quite cantankerous.
- In fact, he eventually tries to explain his GI symptoms through music.
- You examine the abdomen, then recommend fluid restriction and total abstinence from wine.

Beethoven's Autopsy – March 27, 1827 (Vienna)  
Conducted by  
Johnathan Wagner and Karl von Rokitsky  
Assistant bey'm pathologischen Musäum

- "... The body was emaciated, especially arms and legs, and covered with petechiae"
- "... The lower abdominal region was inflated and tense"
- "... The right thoracic cavity contained an abnormal accumulation of serous fluid"
- "... Four quarts of a cloudy grayish-brown liquid were found in the abdominal cavity"
- "... The liver was shrunk to half its volume, hard as leather, and infested with pea-sized nodules on its bumpy surface as well as inside the organ itself"
- "... The spleen appeared twice the normal size, black and rough"

## ASCITES

- The presence of free fluid in the abdominal cavity.
- An important clinical finding, and like pleural effusion usually the result of one of three problems:
  1. *Increased hydrostatic pressure* (right-sided or biventricular failure)
  2. *Decreased oncotic pressure* (from either malnutrition or protein loss -- such as in cirrhosis, nephrosis, and enteropathy).
  3. *Peritoneal inflammation* (neoplastic or infectious).

## PRE-TEST PROBABILITY OF DISEASE

- Look for history of liver disease, plus any recent weight gain, increased abdominal girth, and *ankle swelling*.
- The latter is a *sine qua non* for ascites, due to both *hydraulic* (compression of the leg veins by the ascitic fluid) and *oncotic* reasons (hypoalbuminemia)
- In patients with < 20% chance of having ascites (because of *absent* liver disease by history), lack of recent ankle swelling further decreases the probability of ascites to less than 2.5%.

## PHYSICAL EXAM IN ASCITES

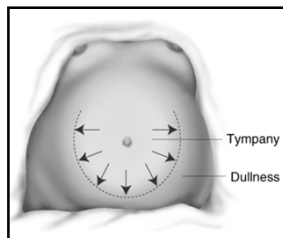
- Convenient and inexpensive, but only valuable for 500-1000 cc of ascites.
- For smaller amounts the diagnostic gold standard remains ultrasonography, which can identify as little as 50-100 ml of fluid (and at a cheaper cost than CT).
- There are four classic maneuvers for the bedside detection of ascites:
  1. Inspection for *bulging flanks* (sensitive but not specific)
  2. Percussion for *flank dullness* (sensitive but not specific)
  3. The *shifting-dullness* maneuver (sensitive but not specific)
  4. The *fluid-wave* test (*specific* but not sensitive)

## BULGING FLANKS

- The Mae West abdominal shape of supine patients with ascites.
- Due to the weight of intra-abdominal fluid (and the effect of gravity on the fluid), the flanks of a supine patient are pushed outward, almost resembling the belly of a frog.
- This same shape, however, may be seen in obese patients.
- Hence, to separate the two conditions one might resort to the *flank-dullness test*...

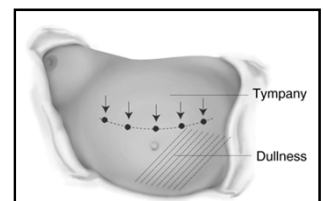
## FLANK DULLNESS TEST

- Percussion of the abdomen in a radiating and outward pattern from the umbilicus toward flanks and symphysis.
- Since gas-filled intestinal loops (resonant) float on top of ascites (dull), the maneuver reveals periumbilical tympany, flanked by dullness.
- *Flank dullness* (and *bulging flanks*) are both very sensitive ( $\geq 72\%$  and  $\geq 80\%$ , respectively) but poorly specific.



## SHIFTING DULLNESS MANEUVER

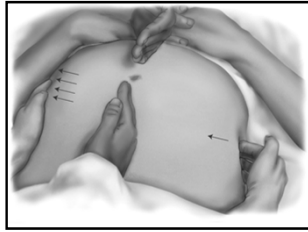
- A gravity-dependent shift in dullness of at least 1 cm (with the shifting border *remaining horizontal*).
- The maneuver is quite *sensitive* ( $\geq 83\%$  in two separate studies), indicating the at least 500-1000 ml of fluid.
- Yet, it has *specificity* of only 50%, the most common confounder being the accumulation of fluid in the colon of patients with diarrhea.
- *Still, given its high sensitivity, a negative shifting dullness argues against the presence of gross ascites*





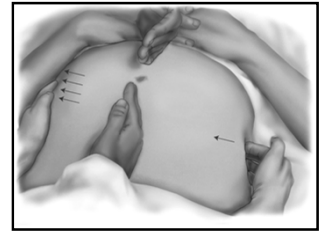
## FLUID WAVE MANEUVER

- With the patient supine, the examiner places one hand on one flank and taps gently on the opposite flank. To prevent a false-positive wave due to flickering of the abdominal wall, the patient places the ulnar surface of one hand vertically over the umbilicus
- The test is positive when there is a fluid wave emanating into the contralateral side.



## FLUID WAVE MANEUVER

- 80–90% *specific* for ascites.
- In fact, it is probably the only truly specific bedside test for ascites.
- Hence, a positive fluid wave can help *rule in* ascites.
- Yet, it still detects only very *large amounts* of ascites (sensitivity 50%).
- Hence, a negative test should not rule out ascites.
- Note that the wave must be *moderate-to-strong* in intensity (slight fluid waves have high interobserver variability and should not be relied upon).



### MANEUVER

### SENSITIVITY (%)

### SPECIFICITY (%)

#### History

Increased abdominal girth	90	60
Recent weight gain	60	70
Ankle swelling	100	60

#### Physical examination

Bulging flanks	70	60
Flank dullness	80	60
Shifting dullness	90	60
Fluid wave	60	90

## ACCURACY OF PHYSICAL EXAM FOR ASCITES

- No single sign or maneuver is both sensitive *and* specific. Many, however, are quite sensitive *or* quite specific.
- There is little interobserver variability in the elicitation of these signs, suggesting that physicians tend to agree on whether a sign is present or absent.
- Overall, in patients with abdominal distention, the most useful signs to *rule out* gross ascites is *absence of shifting dullness* (especially in the absence of ankle edema or recent increase in abdominal girth).
- The most useful signs to *rule in* ascites are:
  - ✓ A positive fluid wave maneuver, and
  - ✓ A history of ankle edema (or liver disease or prolonged PT).
- Diagnostic accuracy can be improved by combining these maneuvers

## ACCURACY OF PHYSICAL EXAM FOR ASCITES (Cont.)

- For example, the fluid-wave maneuver has low sensitivity (50%) but high specificity (80–90%), whereas the shifting-dullness maneuver has high sensitivity (≥83%) but low specificity (55%).
- Thus, their combination provides a decent bedside tool for the diagnosis of ascites, with an overall accuracy that can be around 80%.
- Still, the amount of volume necessary for these maneuvers to become positive (= 500–1000 ml) is much higher than the amount of volume that can be detected by an ultrasound (= 100 ml).

## ACCURACY OF PHYSICAL EXAM FOR ASCITES (Cont.)

- In summary, patients with a history of liver disease, prolonged PT (Bayes Theorem...), and positive fluid wave are *likely* to have ascites and do not need an ultrasound for confirmation.
- On the other hand, patients with normal PT and no shifting dullness are *unlikely* to have ascites, even if they have a history of liver disease; therefore, they probably do not need an ultrasound.

### SPIDER TELEANGIECTASIAS (NEVI)

- Dilated blood vessels that are primarily localized to skin areas where blushing is most intense (face and neck, but also shoulders, arms, hands and torso).
- Conversely, they are very rare on palms, scalp and below the umbilicus, probably reflecting regional differences in neuro-hormonal control of the microcirculation.
- They are compared to spiders insofar as they appear to have both a *body* (the central arteriole) and *legs* (the various radiating branches of the arteriole). They also have an area of erythema, which usually surrounds the teleangiectasia.
- When the "body" of the lesion is compressed with a cover glass slide, it appears to pulsate, and eventually blanches. Upon release of the compression, first the body and then the branches refill.

### SPIDER TELEANGIECTASIAS (NEVI)


- Spider nevi can be present in normal individuals, but in this case tend to be fewer in number (average 3) and smaller in size. Hence, when not otherwise congenital, spider nevi are typically seen in only three conditions:
  - **Liver disease** – In these patients the angiomas tend to correlate with an abnormally increased serum ratio of estradiol to testosterone, and possibly with increased levels of nitric oxide too. "Spiders" also wax and wane according to disease severity.
  - **Pregnancy** – In pregnant women spiders appear between the second and fifth month of gestation, and quickly disappear after delivery.
  - **Malnutrition**

### PALMAR ERYTHEMA

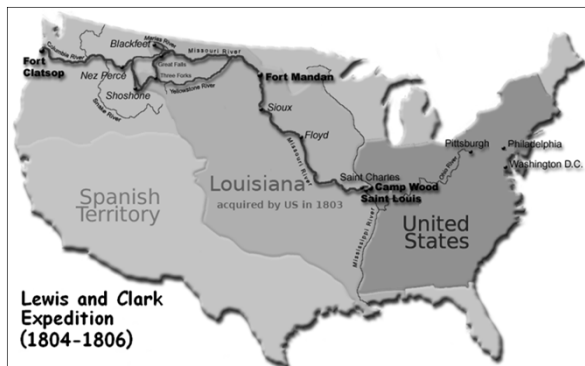
- Like in the case of spider nevi, this is another vascular anomaly often associated with liver disease.
- It is characterized by a symmetric reddening of the palms, mostly over the thenar and hypothenar eminences.
- Erythema occurs in the same clinical conditions as vascular spiders, and the two lesions tend to come and go together.
- Probably due to hepatic inability to inactivate vasodilators, such as nitric oxide.

### CASE

- You are respectively the U.S. President's secretary and a former Lieutenant in the U.S. army.
- After traveling thousands of miles across unknown and unfriendly territory, you return to Washington having lost only one man.
- You report to the President that Sergeant Charles Floyd died of acute belly pain and fever.
- He was buried in 1804 at *Floyd's Bluff*, near modern Sioux City, Iowa.



Meriwether Lewis  
&  
William Clark



### THE ACUTE ABDOMEN (PERITONEAL EXAM)

- Physical examination in patients with peritonitis is crucial for the identification of a surgical "abdomen".
- A set of bedside maneuvers has been developed over the years to help reach a diagnosis, and remains valuable even in our times of MRIs and CT scans.
- Still, individual capabilities play an important role in determining the success (or failure) of these techniques.

### ACUTE ABDOMEN

---

- Guarding (localized/Induced)
- Carnett's sign and AWT
- Rebound Tenderness (Blumberg's Sign)
- Referred Rebound Tenderness
- Abdominal Hyperesthesia
- Stethoscope sign
- Closed eye sign

### ACUTE ABDOMEN

---

- Guarding (localized/Induced)
- Carnett's sign and AWT
- Rebound Tenderness (Blumberg's Sign)
- Referred Rebound Tenderness
- Abdominal Hyperesthesia
- Stethoscope sign
- Closed eye sign

### GENERAL GUIDELINES FOR THE EXAM OF AN ACUTE ABDOMEN

---

- While testing for *guarding* or *rebound tenderness*, always observe the patient's face and not the abdomen.
- Pay special attention to the patient's *expression*.
- Any grimacing or reaction to even a light touch is sometimes the only clue to an acute abdomen.

### THE CLOSED EYE SIGN

---

- This refers to the particular face of patients with nonspecific abdominal pain (i.e., pain without a clear-cut intra-abdominal pathology), who often keep their eyes closed during abdominal palpation, and maintain an embalmed and almost beatific smile.
- This behavior is quite different from that of patients with true intra-abdominal pathology, who keep eyes wide open and monitor very carefully what the examiner's hands are doing.
- Hence, the closed-eyes sign is an accurate test for the recognition of nonspecific abdominal pain.

### THE CLOSED-EYES SIGN - SIGNIFICANCE

---

- Gray et al. studied this sign in 158 consecutive patients admitted for acute abdominal pain.
- The eyes were closed in 6 of 91 patients with true pathology (6.5%), and 22 of the 67 patients with *no* pathology (33%).
- Twenty-two of 28 patients with a positive closed-eyes sign were women ( $p < 0.01$ ), usually young.
- Hence, the predictive value of a positive closed-eyes sign is 79% and that of a negative closed-eyes test is 65%.

### STETHOSCOPE SIGN

---

- This is a technique for patients who are fidgety and resistant to palpation.
- It consists in palpating the abdomen twice, first with your hands and then with your stethoscope.
- Before doing the latter, inform the patient that you are only going to listen to the abdomen.
- This seems to have a distracting effect, and in patients whose pain is either exaggerated or unreal, may allow compression of the anterior abdominal wall all the way against the back (while before a simple light touch had elicited flinching, grimacing, complaining, and quick abdominal tension).
- As always, evaluate the sign in the context of serial observations and the overall picture. There are, in fact, rare case reports of false-positive stethoscope signs in patients with acute appendicitis.

- Lymphnodes
- Abdominal Aorta
- Gallbladder
- Pancreas
- Ascites
- Peritoneum and Acute Abdomen
- Chronic Liver Disease